

UPTAKE

Update on Positron Emission Mammography

By Jean A. Ewing, CNMT, PET, RT(N)(MR), MBA, St. Louis PET Centers, Creve Coeur, Mo.

At the time my PET center took delivery of a positron emission mammography (PEM) scanner in April 2007, it was an extremely new and novel concept in breast imaging. Whole-body PET/CT imaging was already establishing itself as an effective means for the initial staging of breast cancer patients and for evaluating their response to therapy, recurrence and restaging.

Whole-body PET/CT, however, has limitations in resolving lesions less than 2 centimeters in size. The major limitation is the distance between the imaging instrumentation and the lesion. The bore size of the typical PET/CT has to be large enough to accommodate most patients and therefore represents a compromise

between the ideal and reality.

Breast MRI represents an excellent method of anatomic evaluation of the breasts of patients whose mammograms demonstrate a suspicious lesion. Although the sensitivity of breast MRI for detecting lesions is outstanding, the specificity can still leave questions as to whether a particular lesion is malignant. It is in these cases that PEM can be particularly helpful to patients and their physicians.

PEM exploits the ability of fluorodeoxyglucose (¹⁸FDG) to characterize malignant lesions alongside a system design that optimizes resolution by allowing detectors to be placed directly on the patient. The detectors can then produce compression—mimicking mammography—to

Continued on page 4, see PEM

Page 3
SNMTS Elections

Page 5
SNM's 56th Annual Meeting
Mid-Winter Educational Symposium

Page 6
Managing a Specialty Area of Nuclear Medicine

Page 7
Education Schedule

Page 8
VOICE Box

MESSAGE FROM THE PRESIDENT

By Mark Wallenmeyer, MBA, CNMT, RT(N)

The SNM Technologist Section has moved into the second year of its five-year strategic plan. Briefly, our goals state that we will encourage training, networking and an exchange of knowledge; advocate for nuclear medicine and molecular imaging; promote the highest standard of patient care; lead in educational and credentialing/licensing efforts for imaging specialists; and help position technologists within the field of nuclear medicine and molecular imaging.

As my term as SNMTS president draws to a close, I would like to report on our progress in meeting these goals and highlight some of the exciting opportunities awaiting us.

The Board of Higher Education in Arkansas has approved the educational program for the Nuclear Medicine Advanced Associate (NMAA) position. Barring any setbacks, we anticipate the first class, which is supported by the University of Arkansas for Medical Sciences, St. Louis University, and the University of Missouri,



MARK WALLENMEYER

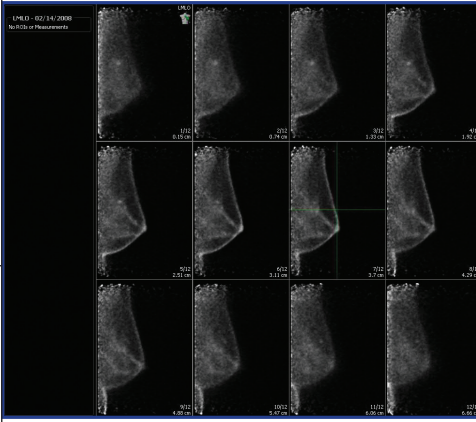
Columbia, will begin in fall 2009.

In addition to the NMAA, we have developed a new, more comprehensive Bachelor of Science entry-level curriculum to ensure that those beginning their education in nuclear medicine are better prepared. The new curriculum includes CT, MRI and other molecular imaging modalities. Also introduced this year were the educational resources and board reviews necessary for preparing for the PET and nuclear cardiology certification exams.

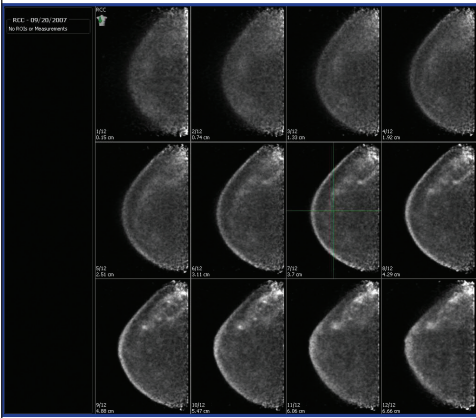
After much anticipation, SNMTS and the Nuclear Medicine Technology Certification Board (NMTCB) launched VOICE credit sharing. This new member benefit will allow SNMTS to transmit continuing education credit data directly to the NMTCB—ensuring that credit is reported accurately and on time. We will be working with the American Registry of Radiologic Technologists (ARRT) during the next year to develop a similar program.

Last year, more than 15 SNMTS members attended "RT in DC"

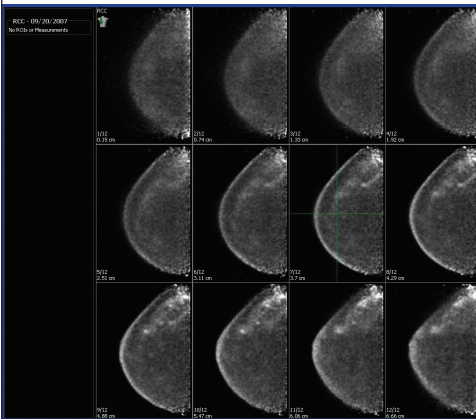
Continued on page 2, see President



Case Study 1



Case Study 2, Pre-Op



Case Study 2, Post-Op

Installing a PEM scanner. The following information should be helpful to those considering purchasing a PEM scanner for their hospital or clinic.

- The scanner requires only a very small space. We placed it in a 10-foot by 10-foot office at our clinic.
- The scanner requires no special power supply and can be plugged into a standard 120-volt outlet.
- No special structural requirements are necessary other than for shielding. [This requirement depends on the state in which the scanner is located, the location of the scanner

allow even better resolution of the breast parenchyma and ductal system.

The following case studies demonstrate the ability of PEM to identify extremely small, discrete lesions. Of particular importance in the first case study was the pathological correlation with the post-PEM biopsy. We also have had several cases where the patient was found to have one or more additional lesions that were not demonstrated on other imaging studies. These findings often changed the management of the patient, a finding that was recently demonstrated in the National Oncologic PET Registry study for whole-body PET.

CASE STUDY 1

History: A 56-year-old patient with biopsy-confirmed invasive ductal carcinoma of the left breast.

Findings:

1. Subtle, punctate focus of mildly increased metabolic activity 12 o'clock position may represent pathologically reported invasive ductal carcinoma; although findings are subtle, with significantly less metabolic activity than expected for a malignant lesion.
2. This subtle punctate focus is not identifiable on whole-body PET/CT.

Follow-up: Post-PEM biopsy of the indicated lesion demonstrated ductal carcinoma in situ.

CASE STUDY 2

History: A 56-year-old patient with ultrasound-guided, biopsy-confirmed, well-differentiated invasive ductal carcinoma of the right breast.

Finding: At least two hypermetabolic upper outer quadrant right breast tissue nodules suspicious for malignancy along with several smaller, less conspicuous and similarly appearing nodules extending into the axillary tail.

History: The same patient returned for a follow-up scan after a right upper quadrantectomy.

Finding: Findings suspicious for a 9 millimeter hypermetabolic residual focus, anterior third of right breast at 10 o'clock position.

What is the future for PEM, and how will it fit into the continuum of breast cancer care?

Results from an independent study of 136 patients showed that PEM was more sensitive than MRI at detecting the smallest cancers. PEM demonstrated 91 percent sensitivity in ductal carcinoma in situ compared with 83 percent for MRI. For lesions less than 5 millimeters, it also demonstrated better sensitivity than MRI (Naviscan PET Systems, Inc.). Results are pending on a 400-patient, multicenter clinical trial in 2008 comparing PEM to MRI. Results from that study should help to clarify how PEM can be used to optimize patient care in conjunction with other forms of imaging, including MRI.

Another development that will likely give PEM an even more secure place in the continuum of care is the recent approval of an accompanying biopsy capability. It is now possible to biopsy patients at the time of their PEM procedure. Because the sample will be radioactive and therefore detectable by the scanner, physicians will be able to see where to biopsy and verify that the sample came from the area seen on the scans. Biopsy specimens can then be scanned to verify that the tumor seen on the images was adequately sampled.

in relation to the general public and the proximity of the scanner to areas where radioactive materials are used and stored.]

- The scanner can be moved easily from one room to another, should the need arise.
- The scanner is nonconfining and works well for patients who cannot tolerate the prone positioning and confinement of MRI scanning.

For more information, please visit Naviscan's Web site at www.naviscanpet.com. ■